Computational Methods for OCT Images Analyze Provided Within Diabetic Retinopathy

Daniela Moraru[1(✉)], Sanziana Istrate[2], Cecilia Eniceicu[3], and Paul E. Sterian[1,4]

[1] Academic Center for Optical Engineering and Photonics, Politehnica University, Bucharest, Romania
moraru.danuta@gmail.com
[2] Ophthalmology Department, "Carol Davila" University of Medicine and Pharmacy, Bucharest, Romania
[3] Ophthalmology Department, University Emergency Hospital Bucharest, Bucharest, Romania
[4] Academy of Romanian Scientists, Bucharest, Romania

Abstract. The paper aims to evaluate the variability of the retinal macular thickness to the glycaemic level in non-proliferative diabetic retinopathy by measuring the retinal thickness using the spectral domain optical-coherence tomography (SD-OCT), during daytime, for patients with diabetic retinopathy (DR) or without diabetes mellitus (DM). The evaluation was carried out using the ImageJ software as a processed method of OCT images from the analysed patients and the Origin 6.0 software as an analytical method of OCT macular thickness data. The paper demonstrated that not only the age of the patients but also the time of the day are significant factors that influence diabetic retinopathy. In addition, the paper also highlights the possibility of controlling retinopathy through differential correction of the glycaemic index at the time the specific medication is provided.

Keywords: Optical coherence tomography · Diabetes mellitus · Diabetic retinopathy · Macular retinal thickness · ImageJ

1 Introduction

In the first part of this paper, are shown some aspects regarding Optical Coherence Tomography (OCT) from both theoretical and biomedical point of view. Also the paper contains some information about Diabetes Mellitus (DM) and Diabetic Retinopathy (DR) as important elements in understanding the study field of interest. In the second part are presented the method we used in data collecting: patients characteristics, instruments, timetable, investigation type. In the same time, we included in this paper the way we used ImageJ in making supplementary distances measurements, as OCT offered directly. The paper is continuing with results presentation, using graphics for comparison between OCT data and ImageJ data, for all foveolar zones. This paper is ending with conclusions regarding obtained results.

© Springer Nature Switzerland AG 2019
S. Misra et al. (Eds.): ICCSA 2019, LNCS 11620, pp. 249–256, 2019.
https://doi.org/10.1007/978-3-030-24296-1_21

This paper compares overall data provided automatically by OCT device for retinal macular thickness with data provided by individual measurements of retinal layers thickness. More than that the comparisons are made for all three macular sectorial zones, in order to provide a more detailed analyses of variability of these thicknesses with glycaemic level.

Optical Coherence Tomography (OCT) is a broadband lower coherence interferometric imaging technique which measures the backscattering light from the sample to reconstruct the depth-resolved structures. Depending on the implementation scheme, OCT can be categorized into time-domain OCT (TD-OCT) and Fourier-domain OCT (FD-OCT). FD-OCT can be realized by different configurations of light sources and detectors, such as point-scanning spectral domain OCT (SD-OCT), and point-scanning and full-field swept source OCT (SS-OCT). The collected data is equivalent, or equivalent under a Fourier transform along the axial/wavenumber axis [1].

Other specialized papers as [2, 14]: indicate the following OCT methods frequency domain (FD-OCT), time domain (TD-OCT) and spectral domain (SD-OCT). The last one could be of two types: based on a spectrometer (SB-OCT) or having laser with controlled frequency (SS-OCT). The swept-source version proves to be the fastest OCT methods who offers enough clarity of in vivo images. For both spectral-domain methods it is a limitation for coherence length for interference who is decreasing with increasing the emitting spectral length. The advantage of this method consists in N times greater sensitivity (N being the number of spectral windows in OCT) and in superiority regarding acquisition data rates (a much better signal/noise ratio).

The intensity of the light incident upon the detector (1) is given by recombination of the light in both arms of the interferometer:

$$\langle I \rangle = \langle I_r \rangle + \langle I_s \rangle + 2Re\left[\left\langle \Psi_r^*(t, z_r) \cdot \Psi_s(t, z_s) \right\rangle\right] \tag{1}$$

where $\Psi(t, z)$ is the light-amplitude field vector, subscripts r and s denote the reference and the sample arms, respectively, z_r and z_s are the optical path lengths (see Fig. 1), and the angle brackets denote ensemble averaging.

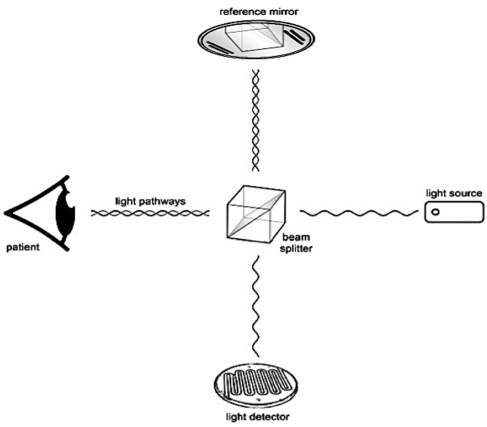

Fig. 1. Functioning principle of OCT based on interferometer

The source spectral density $S(\omega)$ is assumed to be Gaussian (2):

$$\left\{\propto exp\left[-(\omega-\omega_0)^2\Omega^2\right]\right\} \tag{2}$$

with

$$\text{FWHM} = 2\Omega\sqrt{ln2}\,\text{rad/s} \tag{3}$$

Optical Coherence Tomography is used as a non-invasive and in-time imaging method of in vivo tissues, where the new technological methods of the microsurgery and nanotechnology are present [3, 4]. This investigation method is very valuable for medical fields, because it has the capacity to deliver tissues images with high depth resolution, histologic visible. OCT is of interest to ophthalmology, to dermatology, to dentine imaging or, using catheter, to internal organs.

Diabetes Mellitus (DM) has become one of the most prevalent health worldwide problems during last years. Type 2 of DM as the most common form of DM typically occurs in adult patients; meanwhile Type 1 diabetes typically occurs in young patients.

If in 2013 the estimated number was 382 million people suffering from DM and 415 million in 2015, this number could rise to 592 million in 2035, or 642 million in 2040 [5]. In recognition with this estimation, at European level was developed a strategy based mainly on prevention and control of this chronic disease (arisen from The Joint Action on Chronic Diseases and Promoting Healthy Ageing Across the Life Cycle). [6] The earlier DM is detected the better for patients in avoiding visual loss.

Retinal thickness is calculated by the software of the OCT machine which measures automatically the retinal layers, creating retinal maps that can be compared with the normative database, allowing monitoring of the evolution and treatment in time. Optical coherence tomography can show other characteristics of diabetic retinopathy, like hard exudates from the outer plexiform layer, visualized as hyper-reflective areas, can detect intra-retinal and sub-retinal fluid, visualized as hypo reflective spaces, can even detect subclinical macular edema [7–10]. Through OCT, loss or destruction of other retinal layers can be demonstrated, for example, photoreceptor layer or retinal nerve fibre layer, which helps with the differential diagnosis of decreased vision in a diabetic patient. It is useful in the diagnosis of vitreoretinal interface, epiretinal membrane and vitreomacular traction [11, 12].

2 Methods

The present study was conducted according to an ethical Committee regulation and all patients signed an informed consent.

This study [12] is based on OCT images resulted from investigation of 24 patients with diabetic retinopathy (DR) and 19 patients without diabetes mellitus (DM) as control group. The patients had variable GI values during daytime, at 9.00, 12.00, 15.00

and 18.00 o'clock. The exclusion criteria from the study group consisted in other ocular pathologies than DR, media opacities and score below 7/10. Some works [13, 15] recommended 4 to 7/10 score for a better SD-OCT scanning and over 8/10 score for a high quality.

Our study is based on both OCT images (taken with Cirrus^{TM} HD-OCT model, produced by Carl Zeiss Meditec, Inc., class II, acc. 21 CFR 886.1570) and ImageJ measurement within images provided by OCT for probes from 24 patients with diabetic retinopathy, and 19 patients without diabetes mellitus in the control group, for one or both eyes. Glycaemia level was measured with Beurer GL 42/dl glucometer, and the systemic blood pressure with Beurer BM 44 electronic device.

Cirrus^{TM} HD-OCT model is a computing device which takes and analyses cross-sectional tomograms of anterior and posterior ocular structures (including cornea, retina, optic nerve head layers, macula and optic disc). We used Macular Cube 512 × 128 images acquisition type. On these images we delimitated three relevant zones (central, para-foveolar and peri-foveolar) for our research (see Fig. 2). These are also provided with retinal thickness values by Cirrus^{TM} HD-OCT model computing device (see Fig. 2).

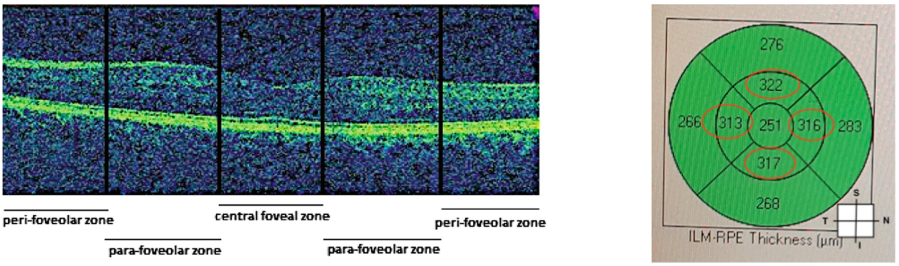

Fig. 2. Zone delimitation on macula cube image type and retinal thickness values provided by OCT device

Particularly we used ImageJ to make distance measurements only on ISel (photoreceptor inner segment ellipsoid) layer (see Fig. 3), as some authors [13, 15] indicate them to be the retinal layers with major influence on eye sight. ImageJ is an open source Java image processing program who can acquire, display, edit, enhance, analyse and animate images. It can be used to measure area, mean, centroid, perimeter, etc. of user defined regions of interest. For a better precision we made three different distance measurements for each zone (marked with black vertical lines). For para-foveolar and peri-foveolar zones, we considered only nasal and temporal sectors.



Fig. 3. Areas delimitation for ImageJ measurements

3 Results and Discussions

In our previous articles [7, 12] we established that it's a correlation between daily variation glycaemic level and retinal thickness, both from OCT perspective and ImageJ measurements. Those works were made only for small parts of foveola. This time we realized an overview on all collected data and, in the same time, a complete comparison between values offered by both distance evaluation method.

Comparing data from Fig. 4 we concluded that diabetic retinopathy has two major influences regarding retinal thickness by itself and its variation with glycaemic index. On one hand, patients with DR have a thicker retina for smaller GI and thinner for bigger GI, than retinal thickness for patients without DM. On the other hand, all foveolar zones (central, para-foveolar and peri-foveolar) are affected in thickness by GI daily variation for patients with DR, presenting a significant decreasing with GI increasing, especially for central and para-foveolar zones. In the same time, for patients without DM, GI variation has almost none influence on retinal thickness, in according with OCT delivered data. It seems that for the first group, retina has a pronounced inertia in establishing basic thickness after an increasing of glycaemia.

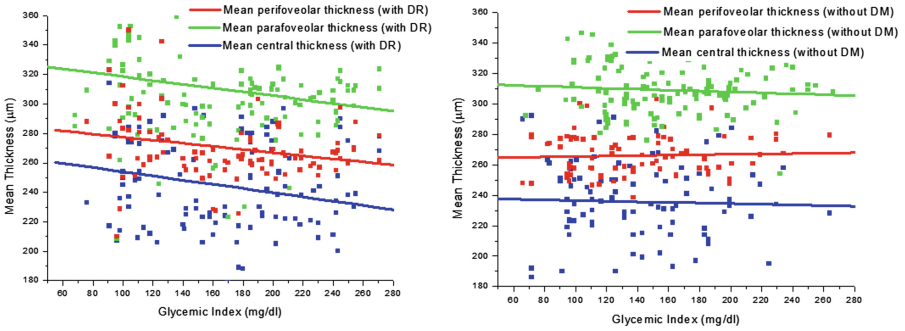

Fig. 4. Retinal thickness variation with GI for patients with DR and without DM

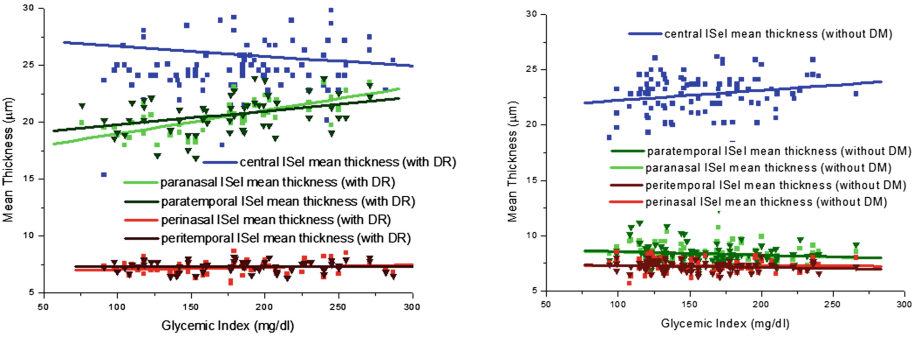

Fig. 5. ISel thickness variation with GI for patients with DR and without DM

From ImageJ measurements we have got graphics from Fig. 5. There is a consistent difference between main value for ISel thickness in para-foveolar zones for patients with DR and without DM.

For patients without DM we obtained almost the same lack of variation as OCT data provided, except central zone where is present a slowly increasing of layer thickness with GI increasing. For patients with diabetic retinopathy measurements have shown instead a consistent increasing of layer thickness in para-foveolar sectors and, in the same time, a considerable decreasing in central zone.

For patients having DR we found a slowly decrease in retinal thickness with increasing of GI, but for ISel we found a consistent increasing of this layer thickness with GI increasing, more obvious for para-foveolar zone, than peri-foveolar zone.

For patients without DM there are small differences between variations at retinal thickness level and variation at ISel thickness level, both for para and peri-foveolar zones.

Another perspective on collected data is the dependence of the retinal thickness by age and moment of the day. Figure 6 illustrates how mean retinal thickness for para-foveolar and peri-foveolar zones is decreasing with age, for both patients with DR and without DM. Only for the central zone, the variations are opposite, being a sensitive increasing for patients with DR.

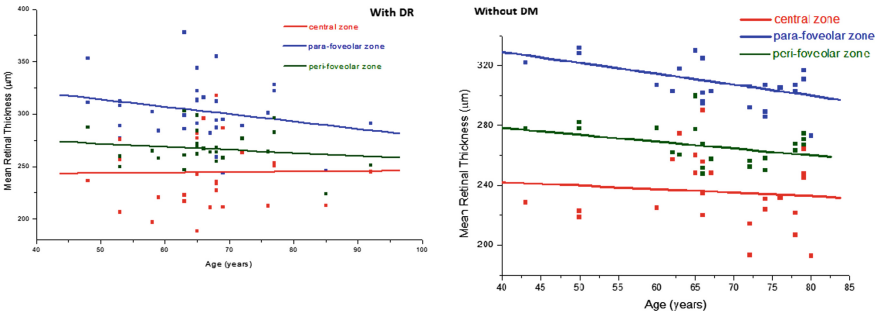

Fig. 6. Mean retinal thickness variation with age for patients with DR and without DM

Figure 7 contains the dependence of central retinal thickness during daytime for both study groups and for different age groups. For patients having DR there is no a significant variation of retinal thickness during daytime for any of age groups. Instead, for the youngest patients (40–60 years old) without diabetes mellitus, there is a consistent thickness increasing during daytime.

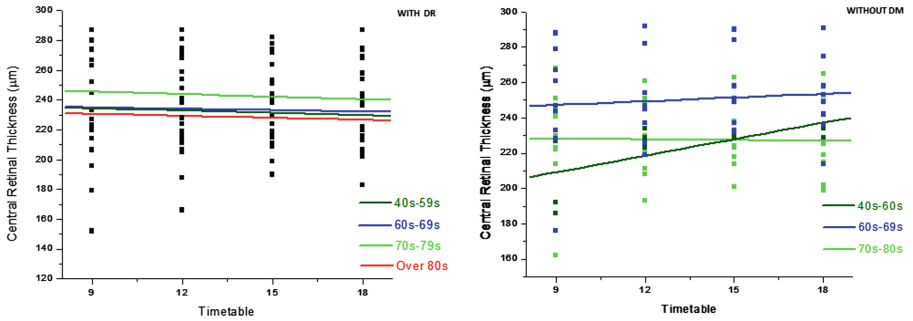

Fig. 7. Central retinal thickness variation with daytime for patients with DR and without DM

4 Conclusions

This study level revealed that glycaemic index daily variation has influence on retinal thickness, but more important for patients having diabetic retinopathy than for those who do not have diabetes mellitus.

Data obtained with ImageJ measurements are almost the same with those resulted from OCT measurements. The biggest difference appeared for para-foveolar sectors, for patients with DR, where the variation in ISel thickness is inversed comparing with variation of retinal thickness. One hypothesis could consist in considering the relevance of energy transformations which are taking place at photoreceptors cells level. The results however correlate with data from literature where the increased retinal thickness in DM is due to the capillary exudations in moments with high glycaemic levels. Probably for retina affected by diabetes tissue rebuilding process is slower and not too efficient.

Our collected data and their interpretations show that this kind of study should be made again, mostly for patients aged between 35 and 60 years old, which retinal thickness variability seems to be partial or totally reversible.

Acknowledgements. All authors have equal contribution to this paper.
The authors declare no financial interest.

References

1. De Boer, J.F., Milner, T.E., Van Gemert, M.J.C., Nelson, S.J.: Two-dimensional birefringence imaging in biological tissue by polarization-sensitive optical coherence tomography. Opt. Lett. **22**(12), 933–936 (1997)
2. Balasubramanian, M., Bowd, C., Vizzeri, G., Weinreb, R.N., Zangwill, L.M.: Effect of image quality on tissue thickness measurements obtained with spectral-domain optical coherence tomography. Opt. Express **17**(5), 4019 (2009)
3. Iliescu, F.S., et al.: Continuous separation of white blood cell from blood in a microfluidic device. UPB Sci. Bull. Ser. A **71**(4), 21–30 (2009)
4. Lazar, B., et al.: Simulating delayed pulses in organic materials. In: Gavrilova, M., et al. (eds.) ICCSA 2006. LNCS, vol. 3980, pp. 779–784. Springer, Heidelberg (2006). https://doi.org/10.1007/11751540_84
5. Kumar, B., Gupta, S.K., Saxena, R., Srivastava, S.: Current trends in the pharmacotherapy of diabetic retinopathy. J. Postgrad. Med. **58**(2), 132 (2012)
6. Richardson, E., Zaletel, J., Nolte, E.: National Diabetes Plans in Europe. World Health Organization 2016 (2016)
7. Moraru, D., et al.: Incursion in a contrast sensitivity changes related to non-proliferative diabetic retinopathy. In: 20th International Conference, Bulgaria, 26–30 June 2018
8. Cunha-Vaz, J., Coscas, G.: Diagnosis of macular edema. Ophthalmologica **224**(Suppl 1), 2–7 (2010)
9. Drexler, W., et al.: Ultrahigh-resolution ophthalmic optical coherence tomography. Nat. Med. **7**(4), 502–507 (2001)
10. Wojtkowski, M., et al.: Ophthalmic imaging by spectral optical coherence tomography. Am. J. Ophthalmol. **138**(3), 412–419 (2004)
11. Sikorski, B.L., et al.: The diagnostic function of OCT in diabetic maculopathy. Mediators Inflamm. 434–560 (2013)
12. Moraru, D., Spulber, C., Istrate, S., Eniceicu, C.: A brief study about the influences of glycemia variations in a non-proliferative diabetic retinopathy. Ann. Acad. Rom. Sci. Ser. Sci. Technol. Inf. **11**(2), 23–34 (2018). ISSN 2066-8562
13. Saxena, S., et al.: Photoreceptor inner segment ellipsoid band integrity on SD-OCT. Clin. Ophthalmol. Dove Press J. **8**, 2507–2522 (2014)
14. Sterian, A.R., et al.: A new possibility of experimental characterization of a time of flight telemetric system. Rom. Rep. Phys. **64**(3), 891–904 (2012)
15. Scoles, D., et al.: Assessing photoreceptor structure associated with ellipsoid zone disruptions visualized with optical coherence tomography. Retina (Philadelphia Pa.) **36**(1), 91 (2016)